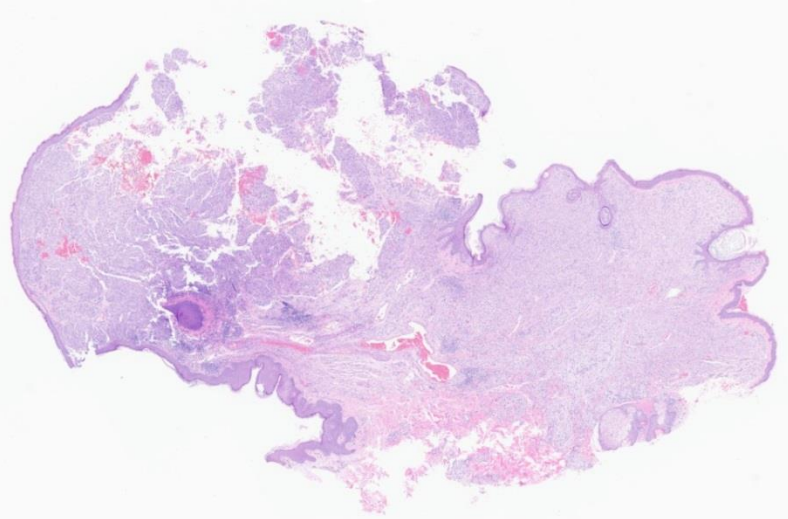
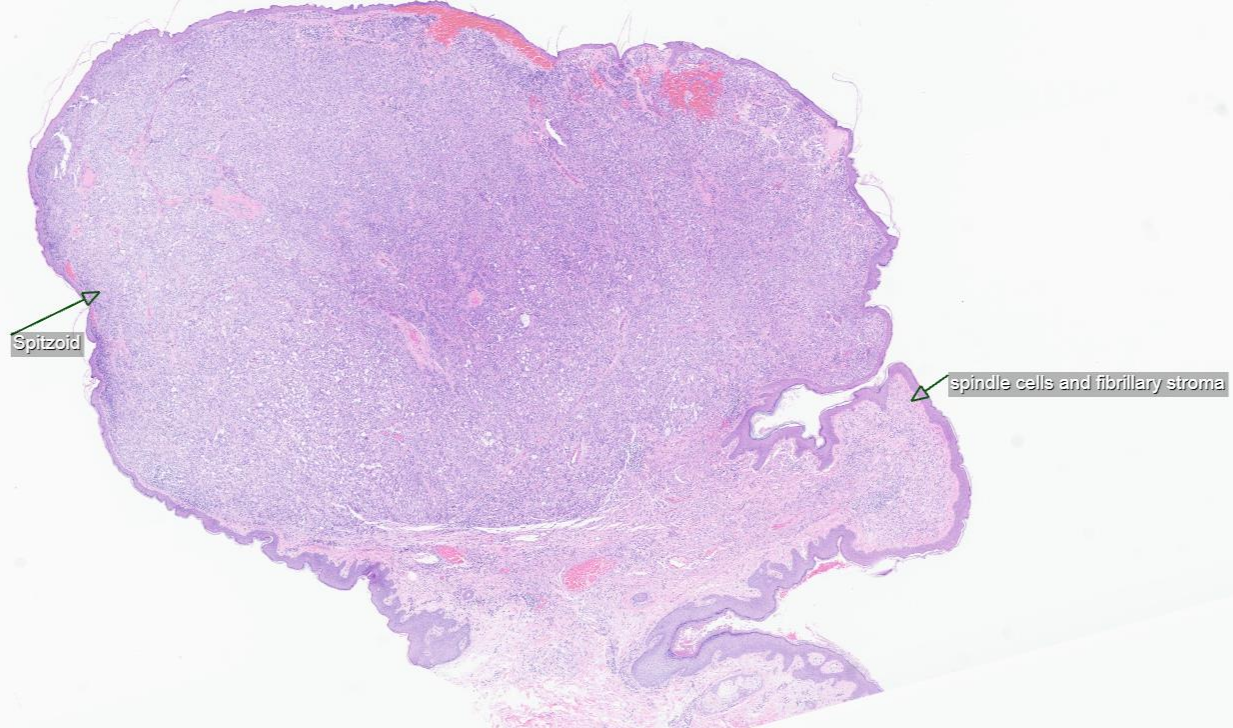
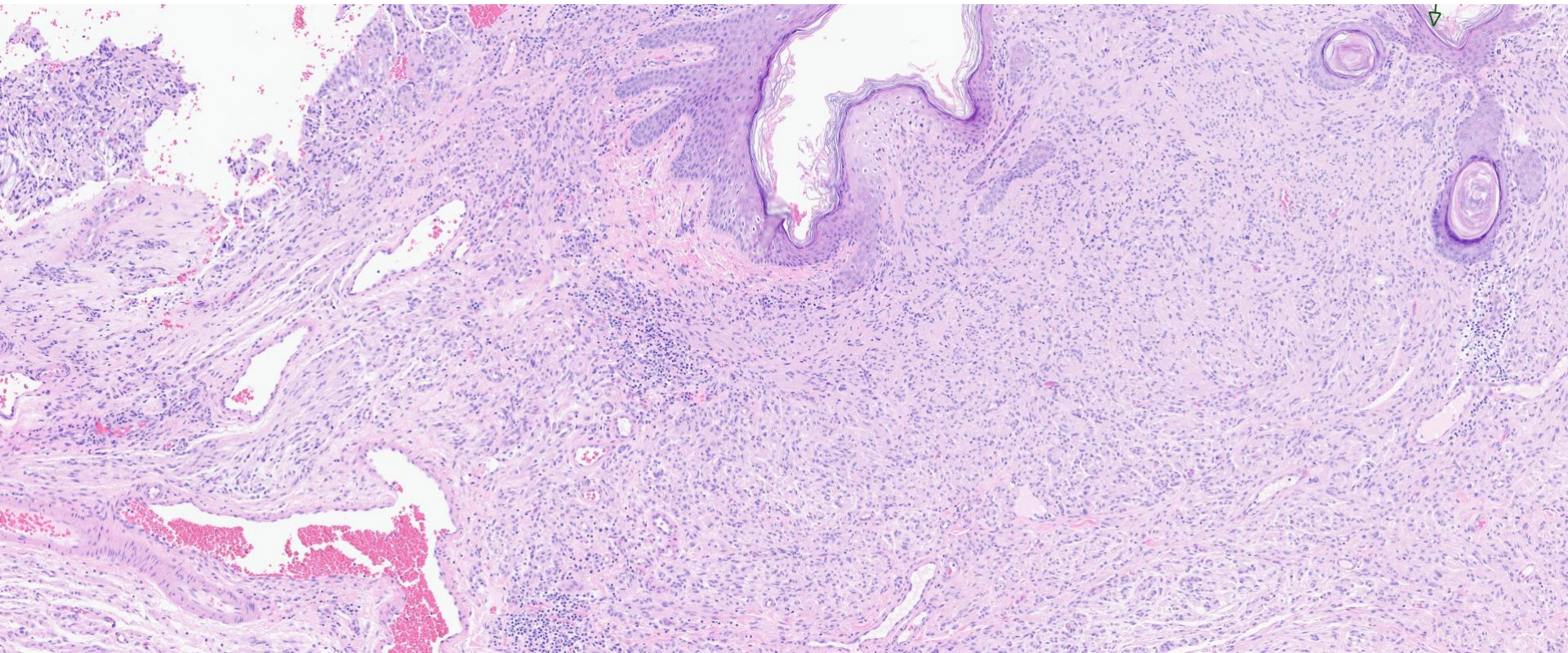
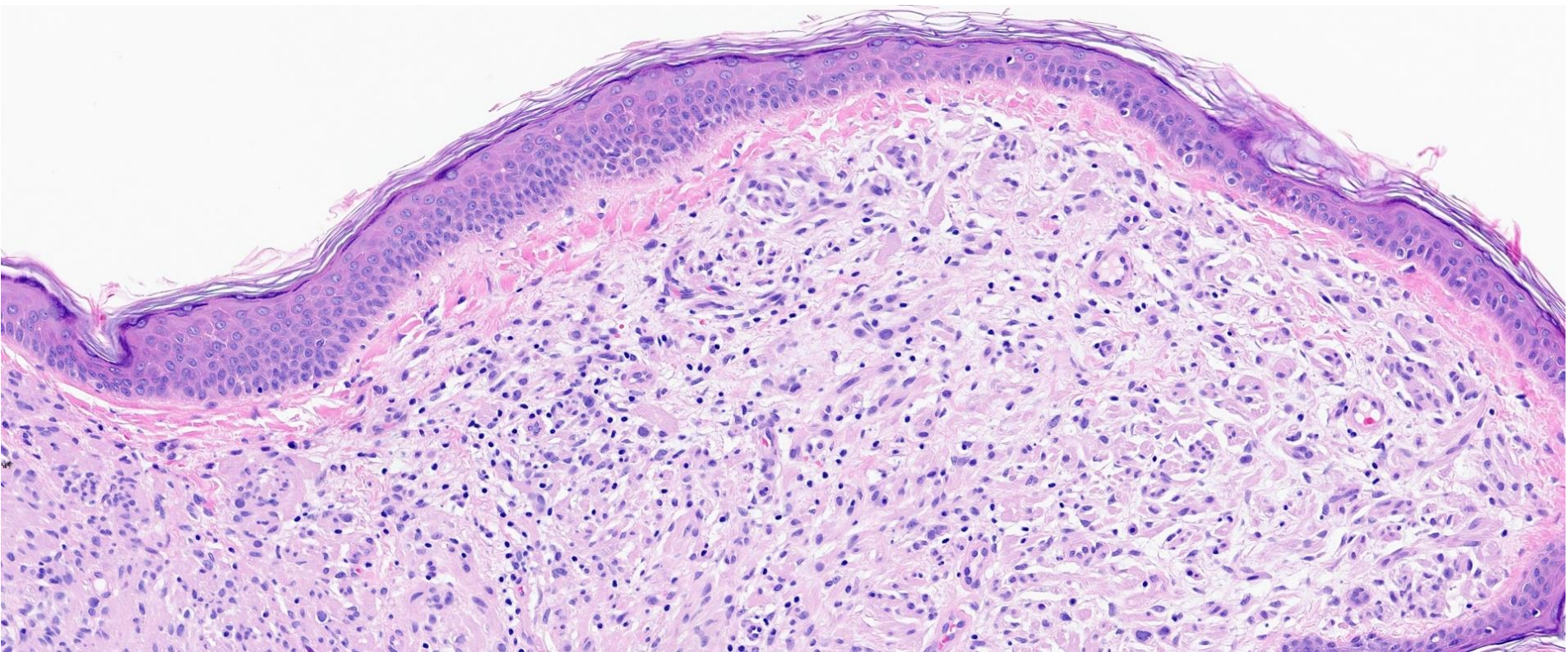


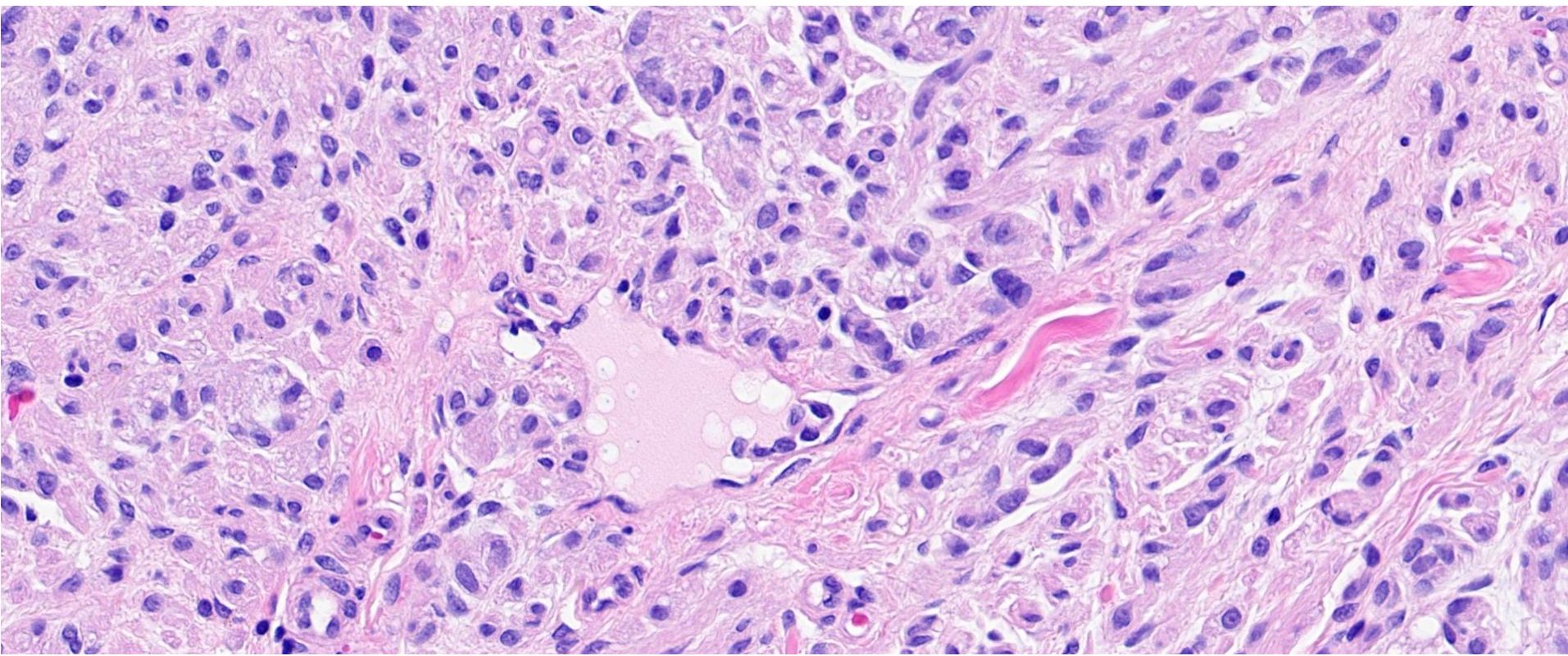
CASE 247 -

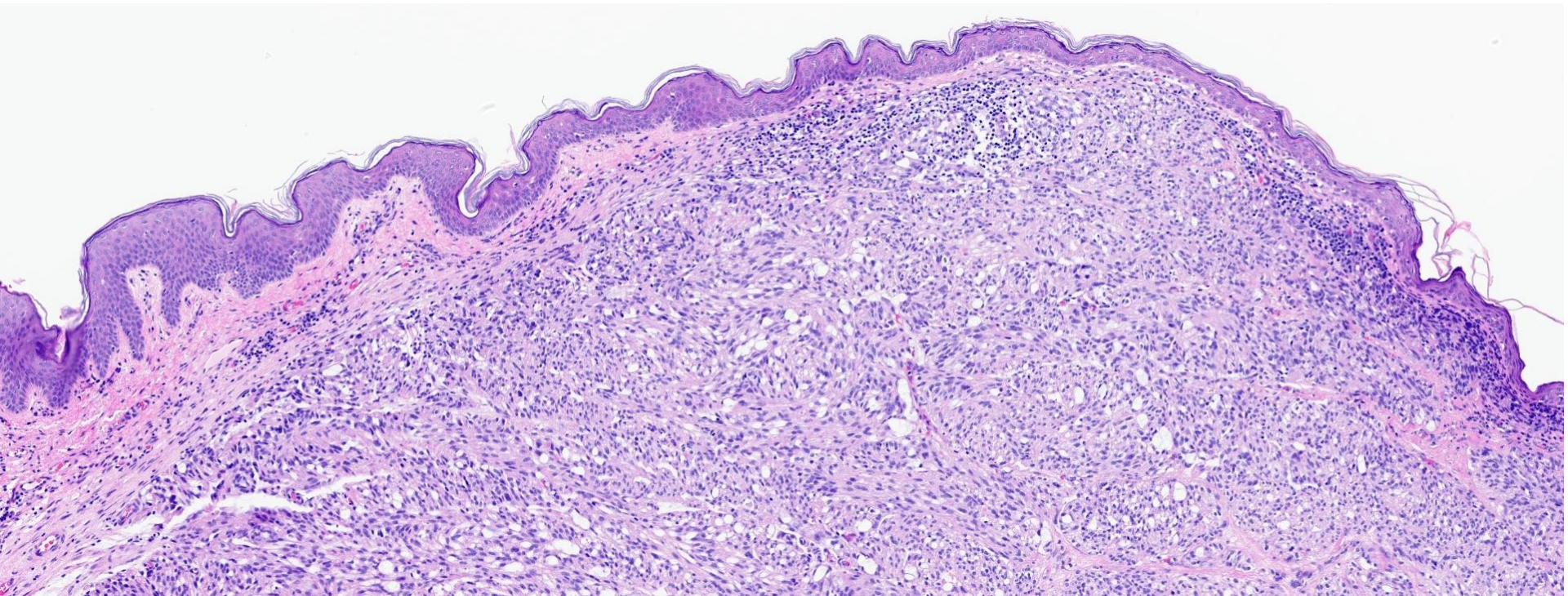
Male 61 years Skin tag left chest wall

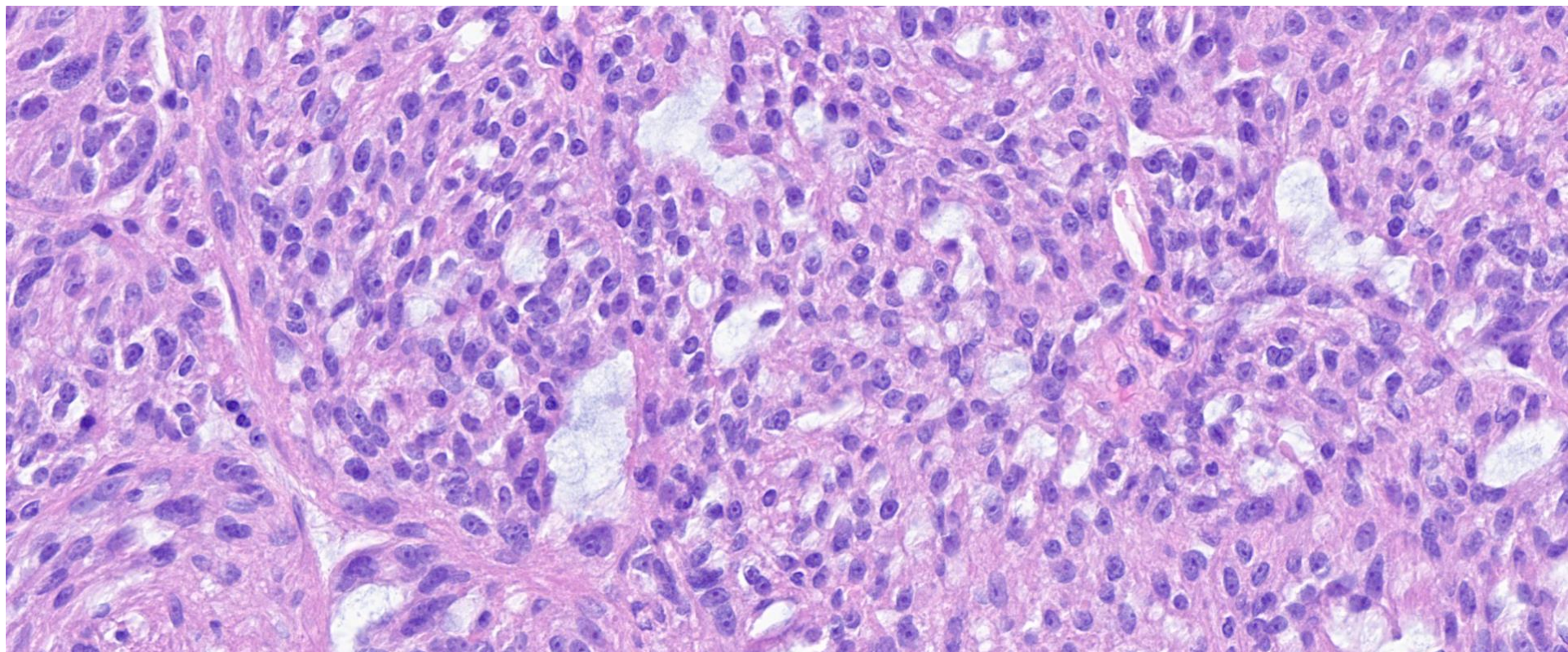












Lesion diameter: 10 mm (occupies the entire specimen)

Vertical growth phase: yes

Mitotic rate (per mm²): 1 per mm²

Breslow thickness: 3.5 mm

Angiolymphatic invasion: no

Perineural invasion: no

Microsatellites: no

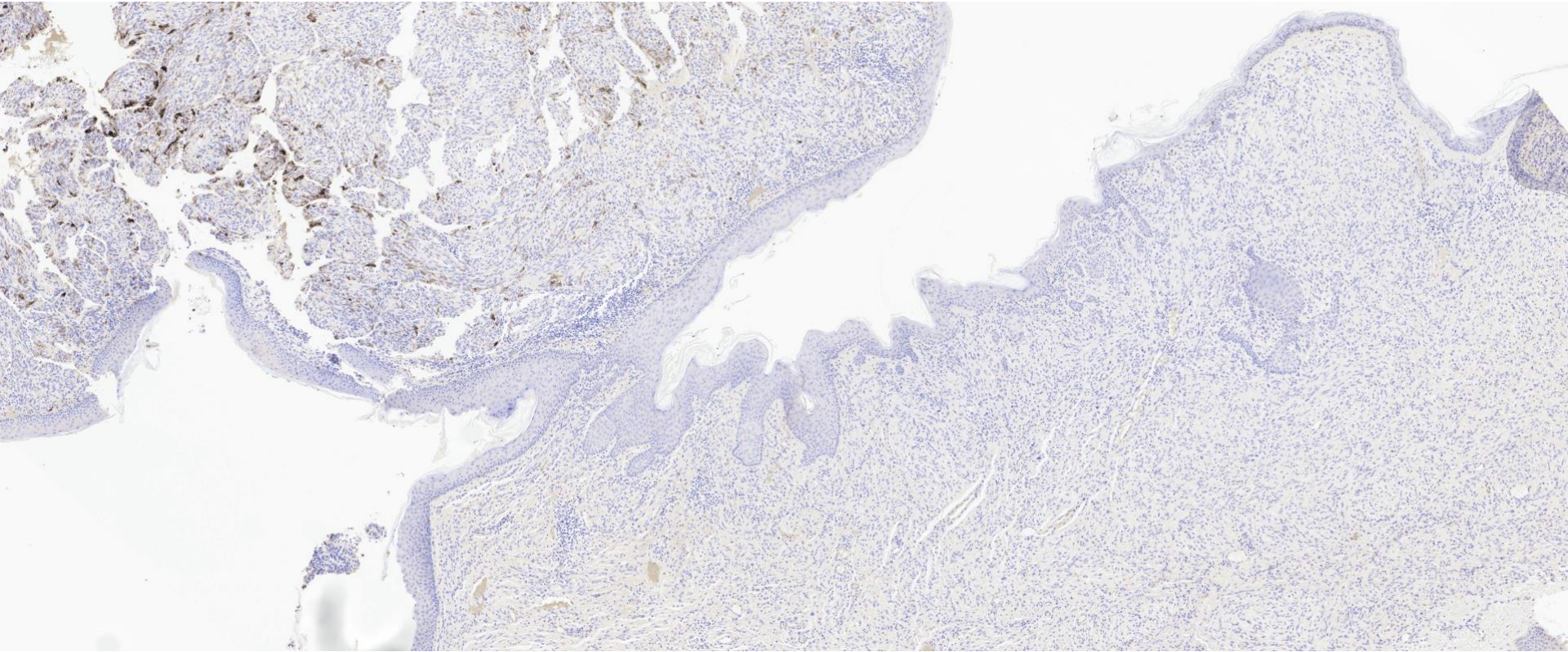
Regression: no

Ulceration: no

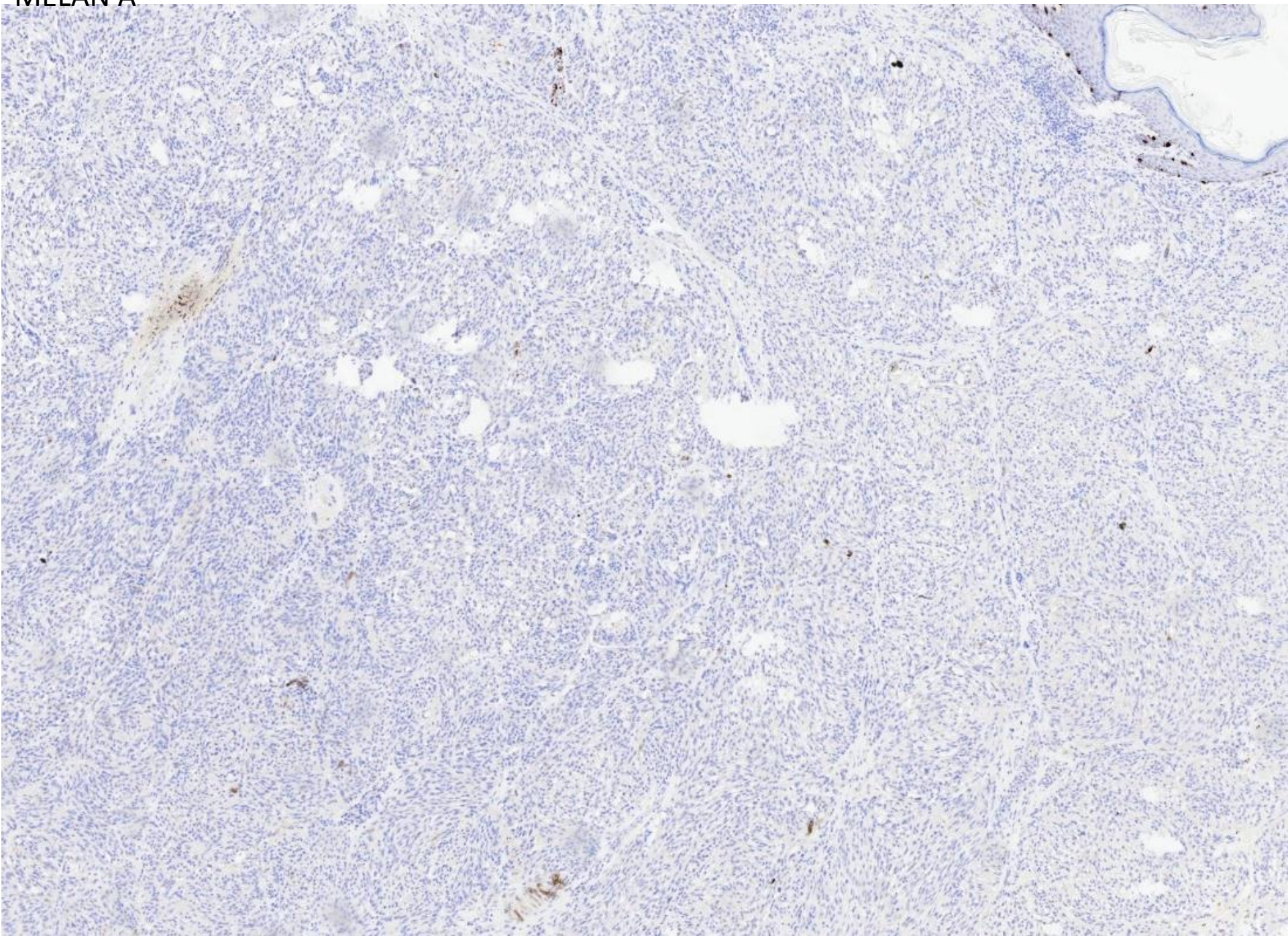
TILS: non brisk

Clarke level: Clarke IV

HMB-45



MELAN A



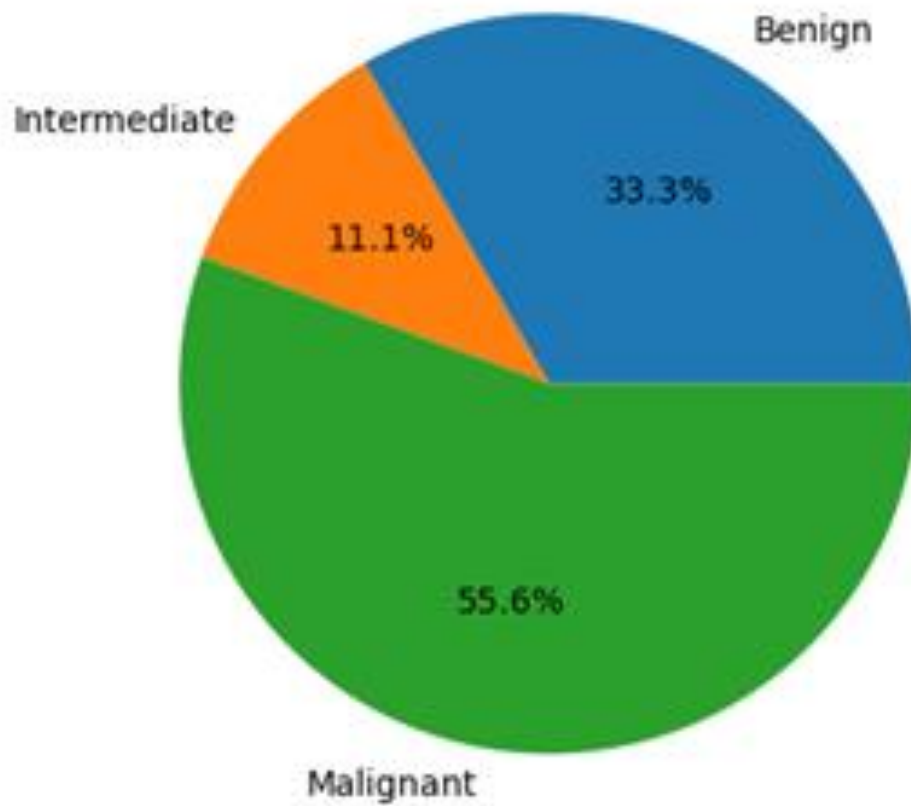
Immunohistochemistry-

Positive - Diffuse SOX 10 and S100, patchy HMB-45

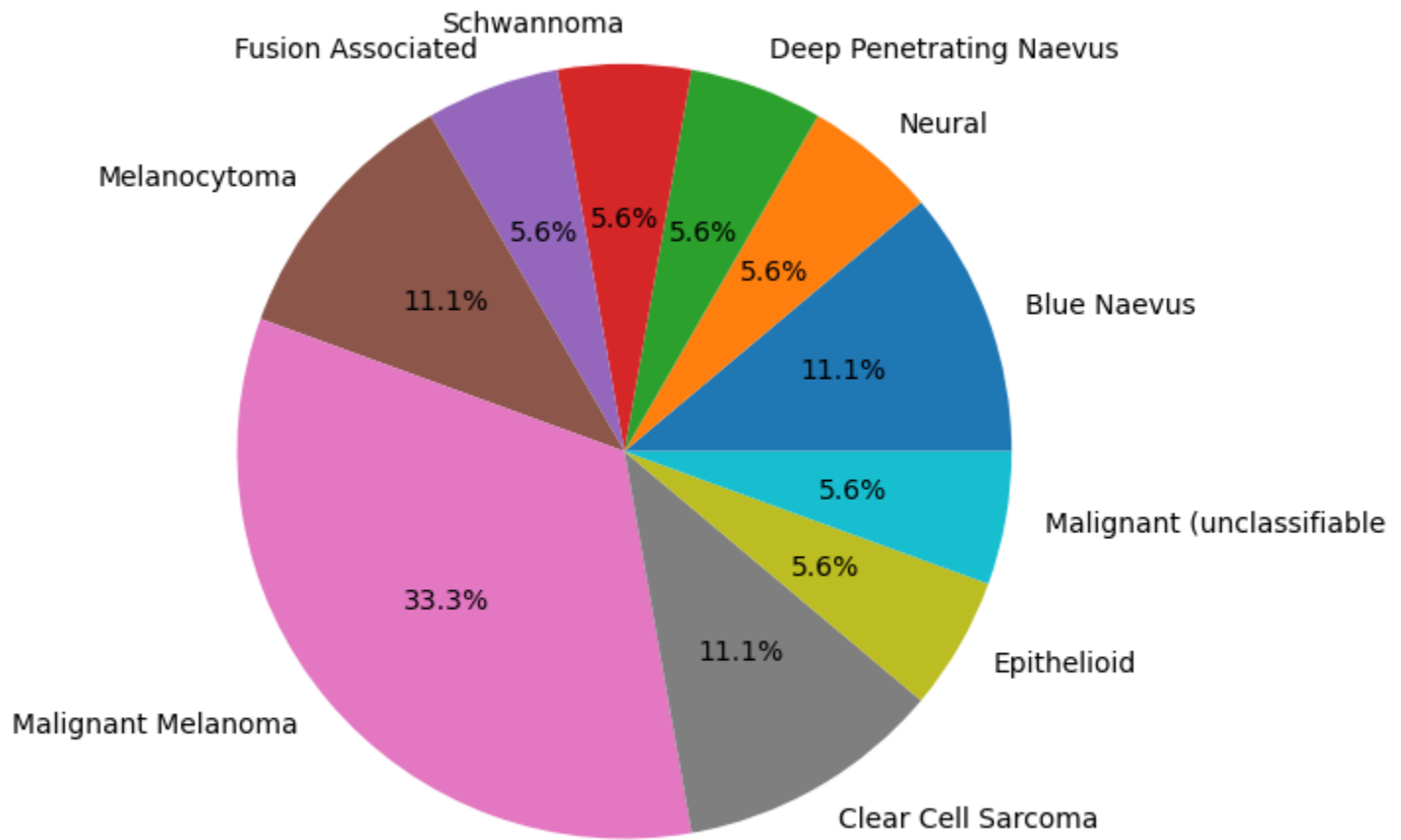
Negative - Melan A undertaken in the originating lab and repeat at our lab,
Desmin.

- B Catenin -Diffuse membranous and cytoplasmic staining
- Ki 67 proliferation fraction is less than 5%

Case 247



Case 247



Skin classifier v0.1

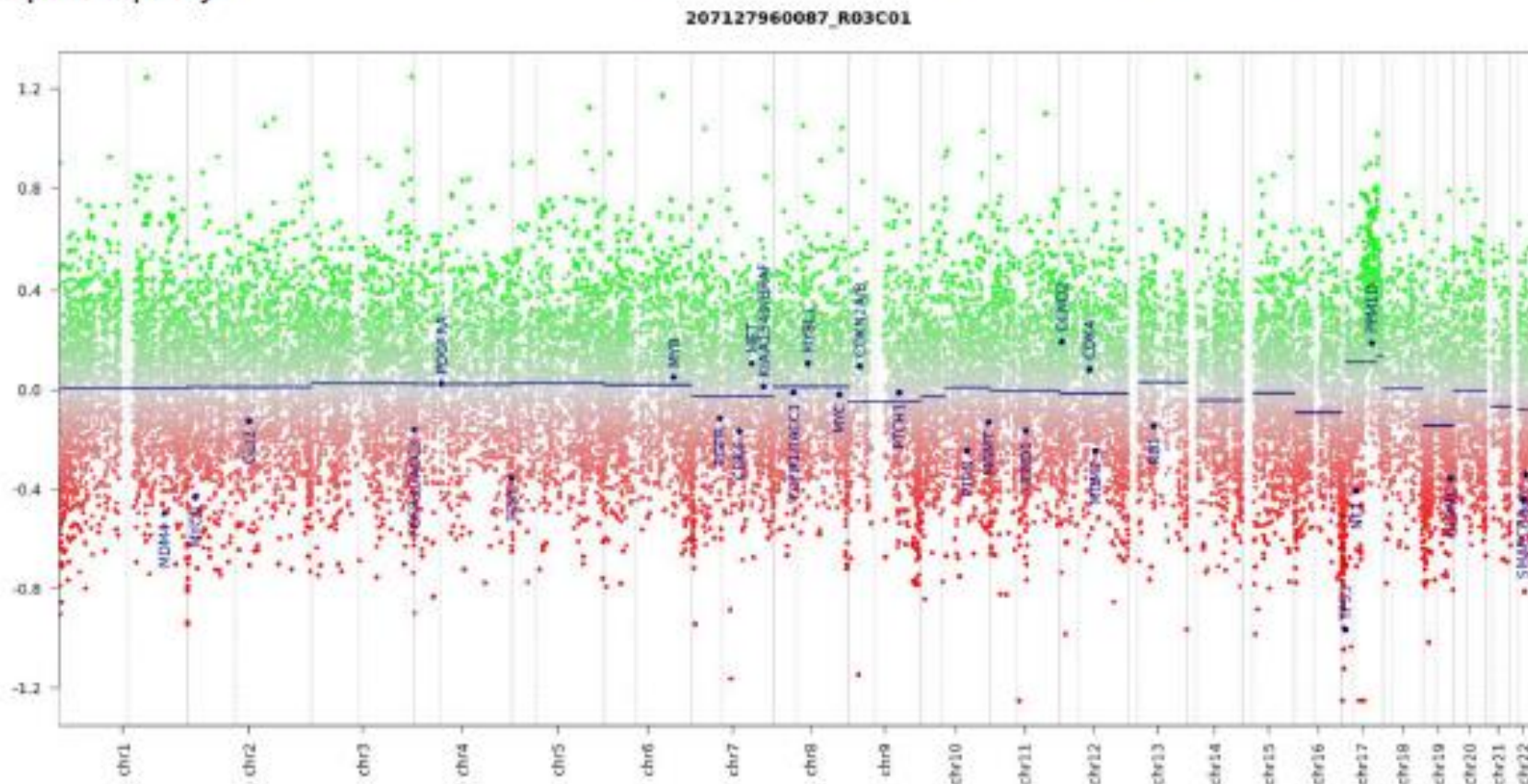
NFIB (score 0.65, no match) →

Copy number variation summary:

GAIN: 17q

LOSS: 17p

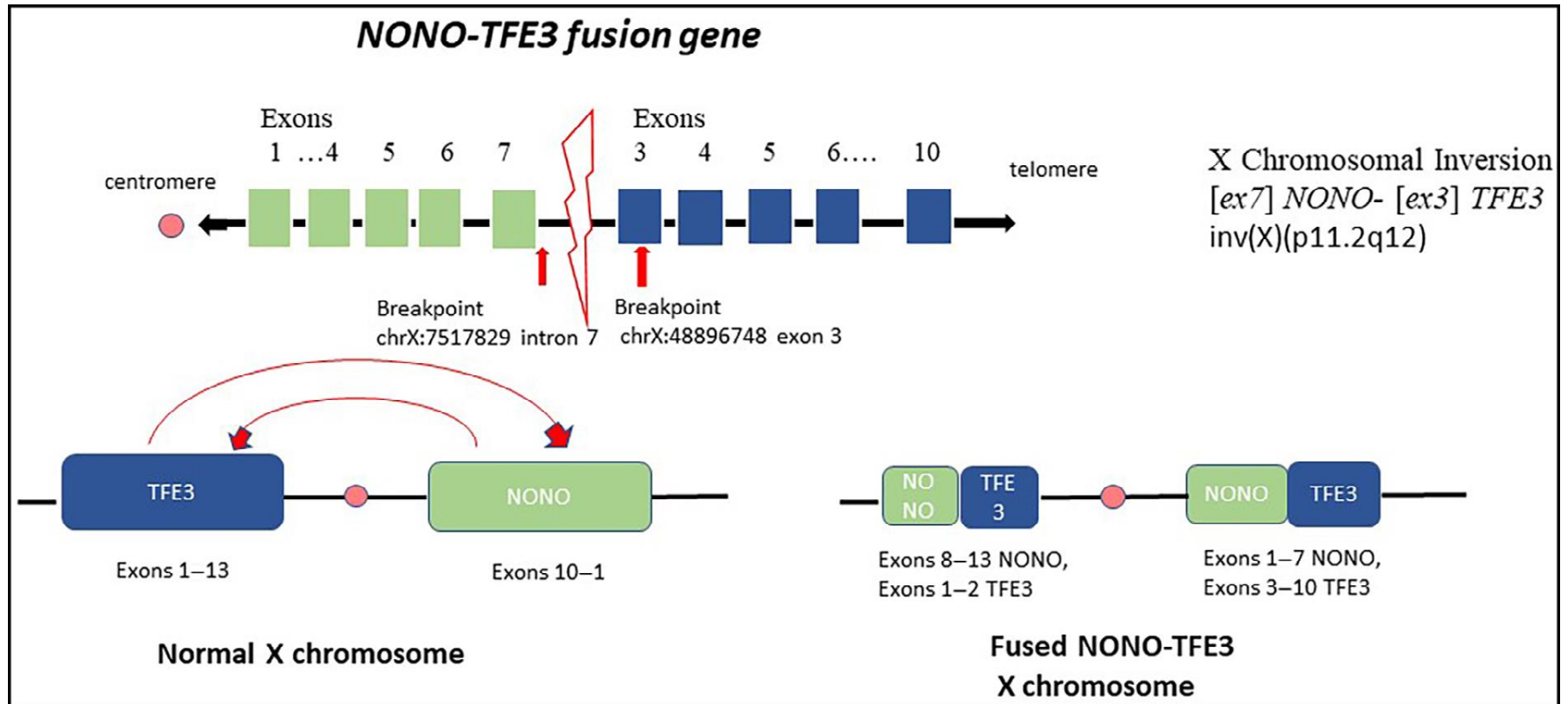
In summary, this plot shows isochromosome 17q although we note that the copy number plot was of sub-optimal quality.



NO EVIDENCE OF BRAF, NRAS, IDH1, IDH2 OR TERT PROMOTER VARIANTS

NO CDKN2A loss on FISH

Illumina TruSight RNA Fusion Panel- **NONO::TFE3 fusion was detected**



NONO::TFE3 fusion described IN

- MiT family translocation renal cell carcinomas
- Rare extracutaneous perivascular epithelioid cell tumors (PEComas), including two from the sinonasal tract, two from the orbit

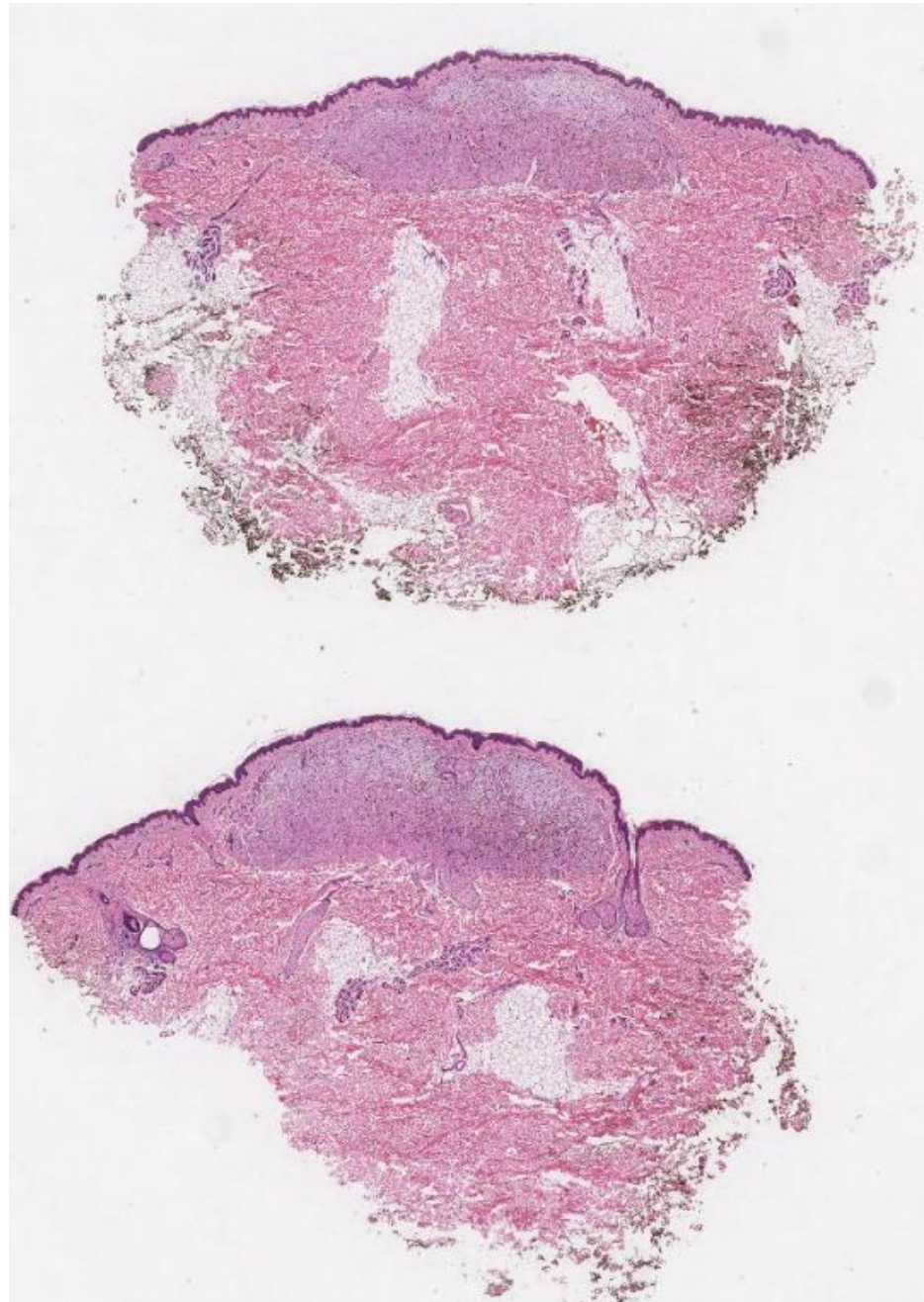
***NONO::TFE3* fusion cutaneous epithelioid and spindle cell tumor: A case series**

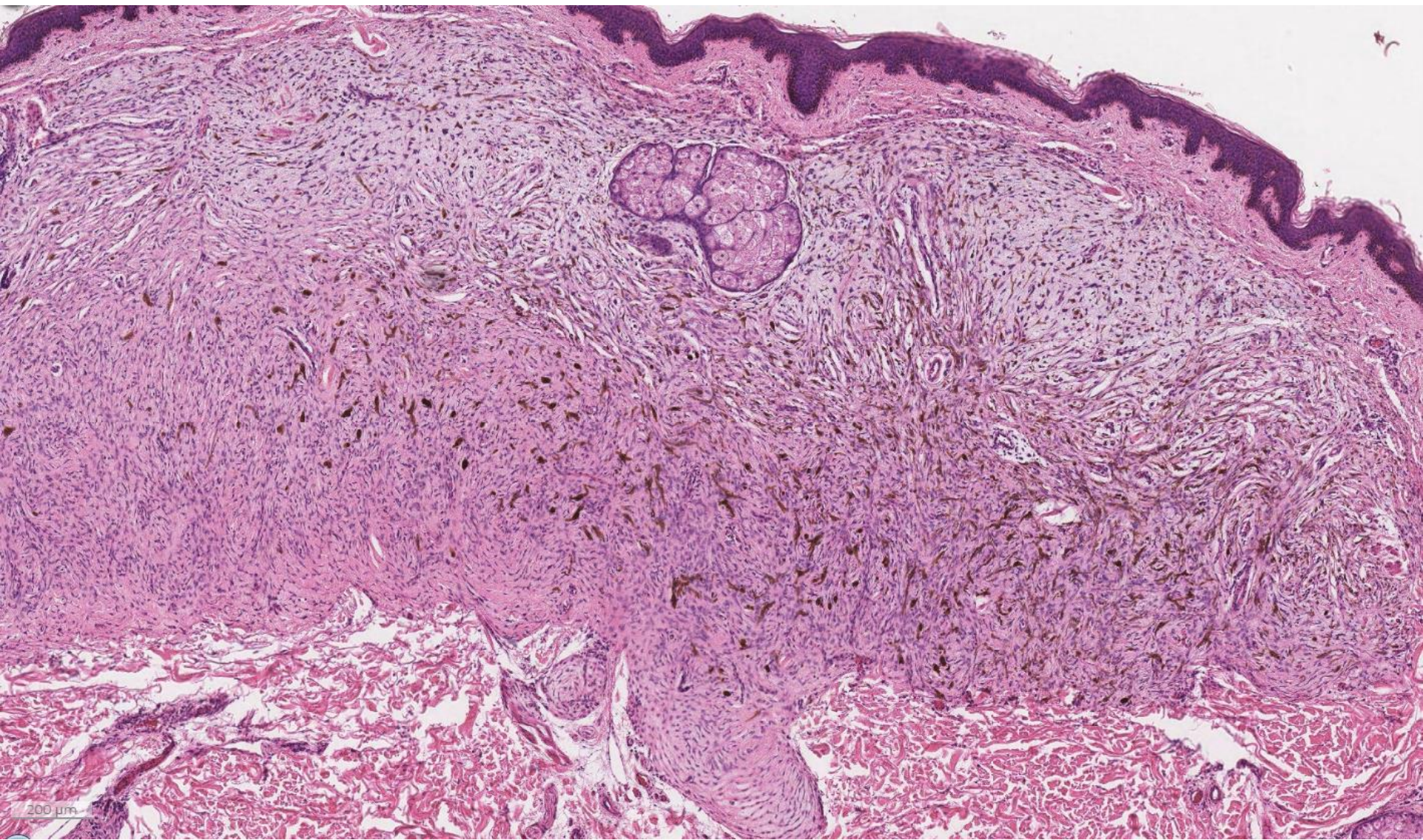
Sharlene Helene C. See¹  | Shantel Olivares¹ | Maansi Kulkarni² |
Soneet K. Dhillon¹ | Monica Stella Fumero-Velazquez¹ |
Michael Norman E. Hagstrom¹ | Pedram Gerami¹

2 Cases

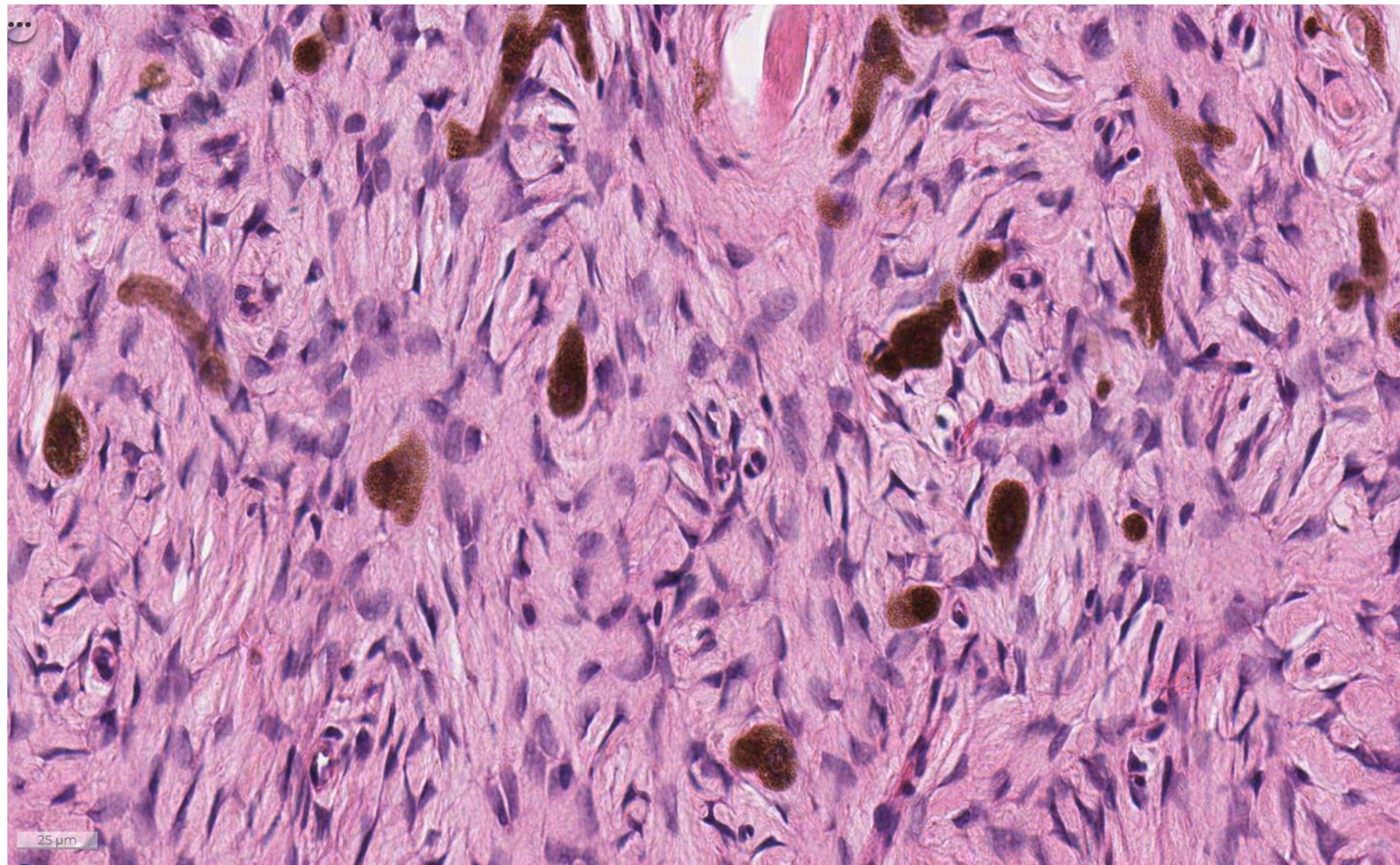
1. 80 Y/M ,erythematous, slow growing, asymptomatic 1.2 cm nodule on the right ring finger
2. 72Y/F, 6 mm growth of unknown duration on the left proximal posterior thigh.

CASE 248 - Male 32 years, Left posterior shoulder.

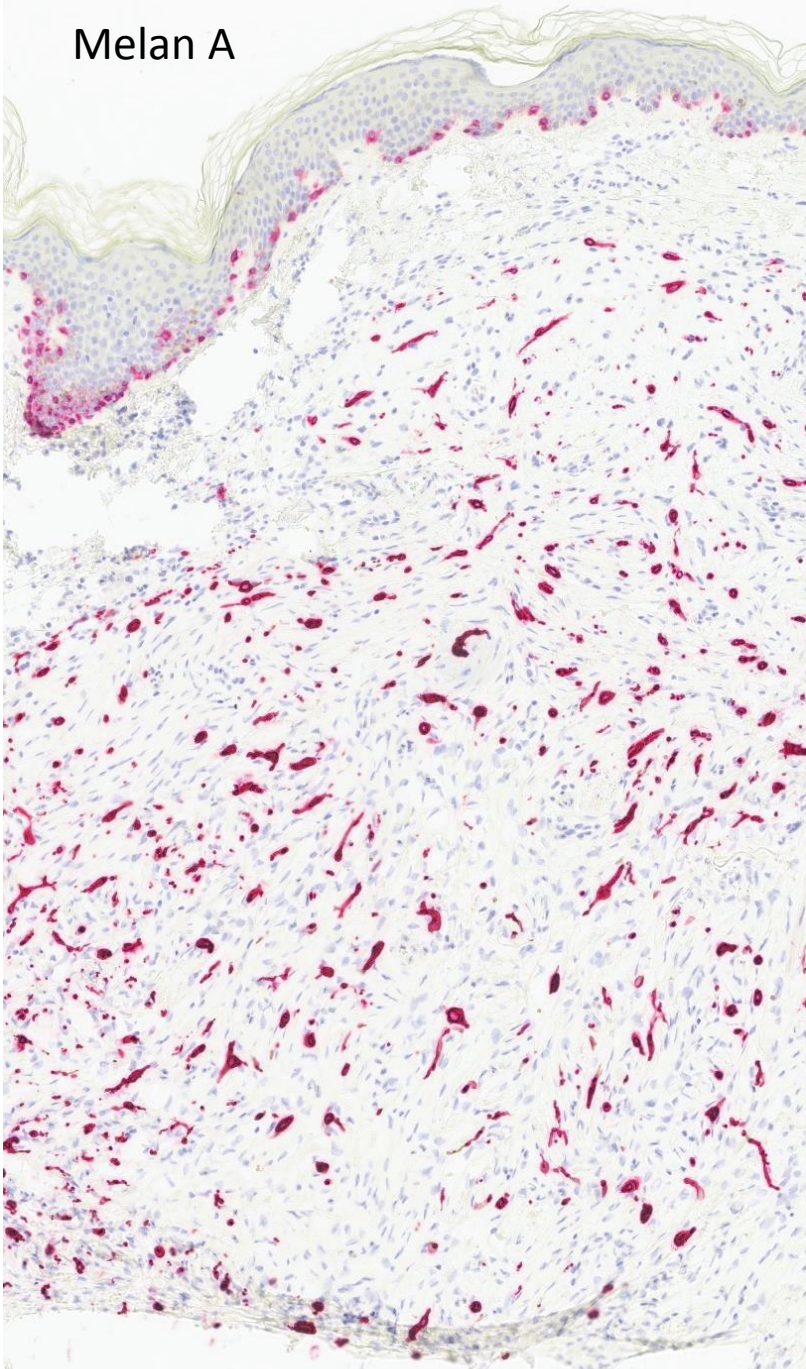




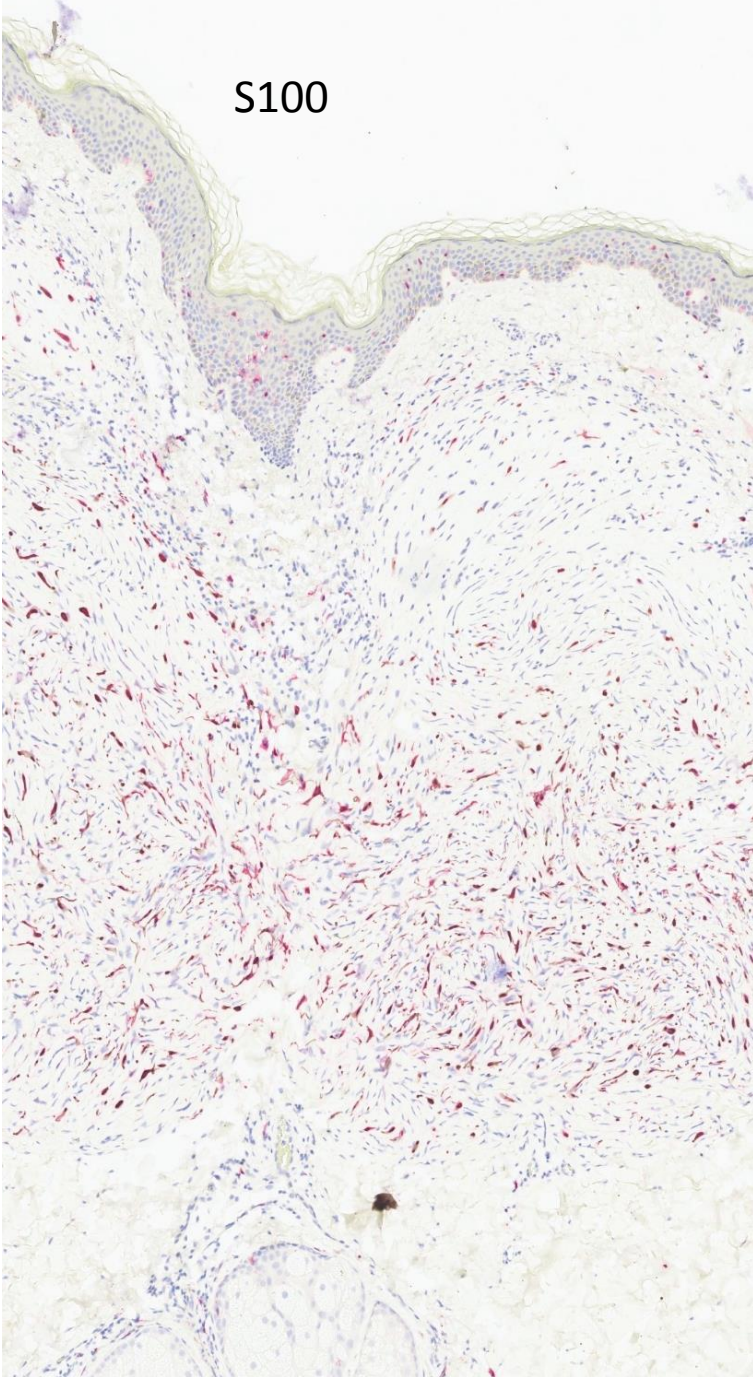
200 μ m



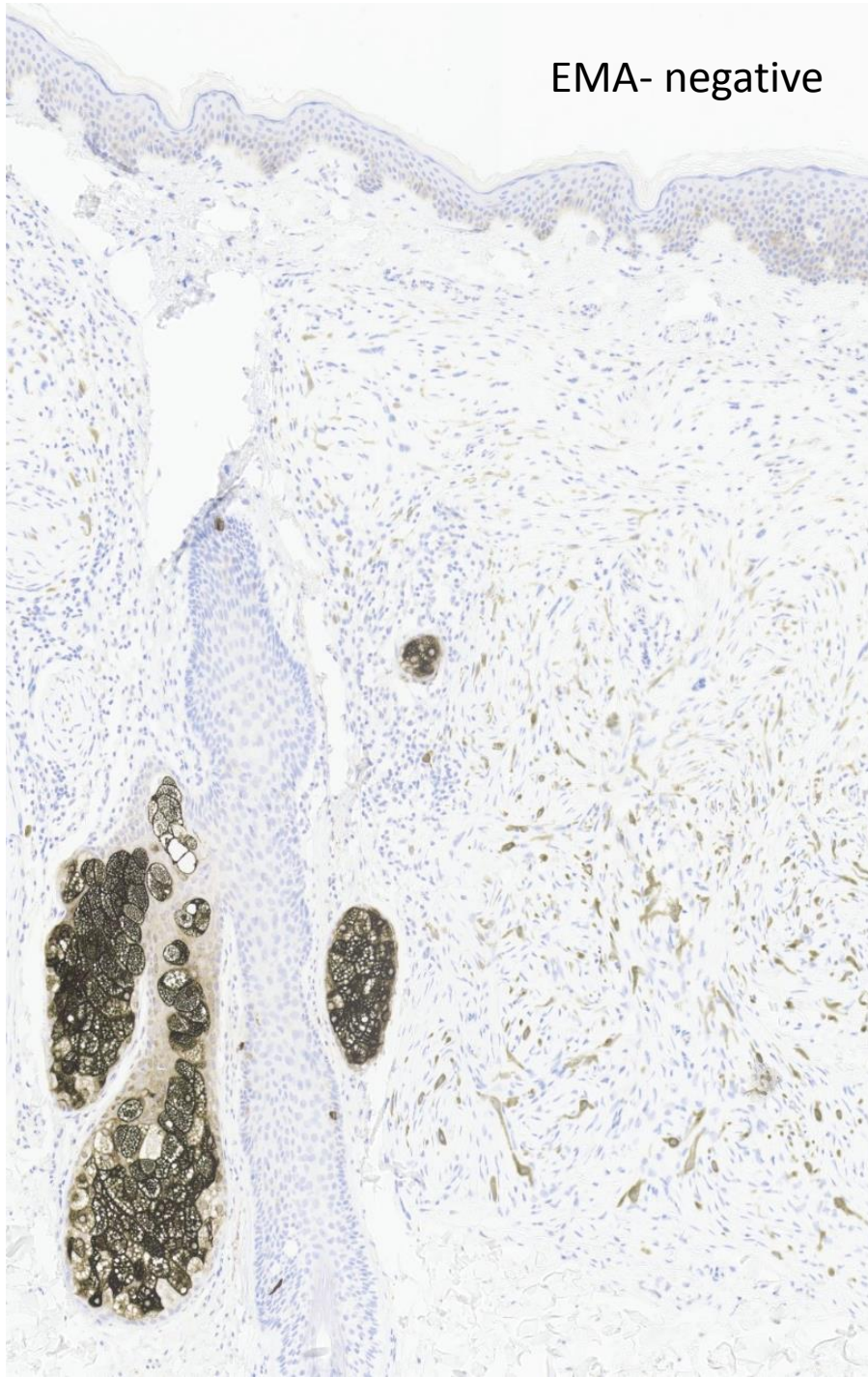
Melan A



S100

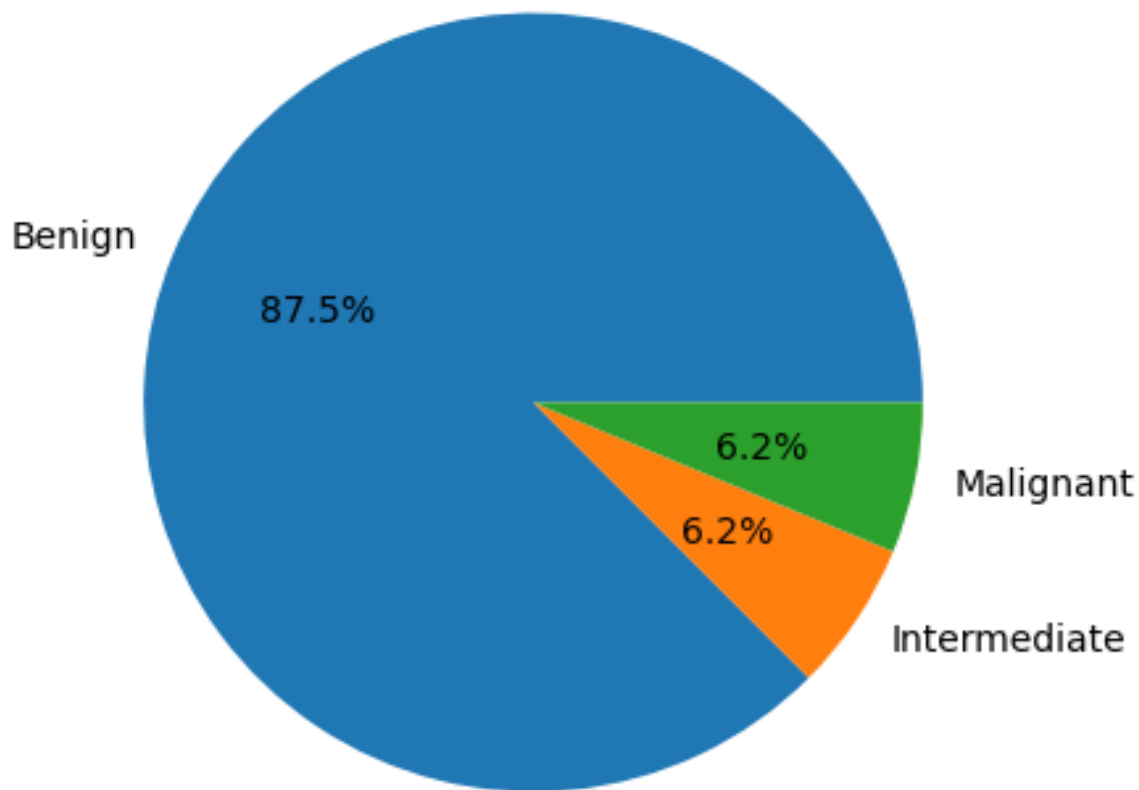


EMA- negative

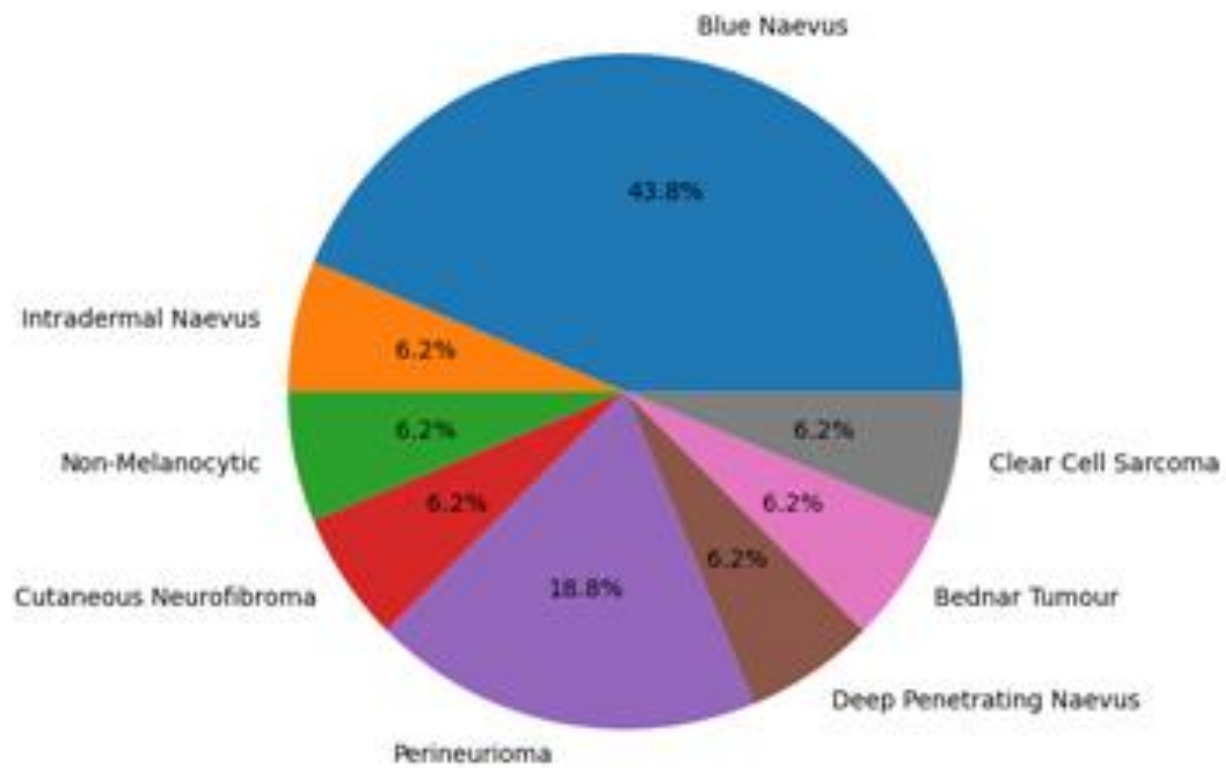


Neurofilament protein- negative

Case 248



Case 248



Illumina TruSight RNA Fusion Panel- **SPECC1L::ALK fusion detected**

No driver variants have been detected in BRAF, NRAS or KIT

FINAL DIAGNOSIS –
SPECC1L::ALK fusion neoplasm, novel entity

SPECC1L (sperm antigen with calponin homology and coiled-coil domains 1-like)

- Encodes a coiled-coil domain protein located on 22q11.23.
- Several recurrent partner genes have been reported to fuse with SPECC1L
 - RET- leads to constitutive RET kinase activation in papillary thyroid carcinomas (Cancer Genome Atlas Research Network 2014; Stransky et al. 2014)
 - MET in lung adenocarcinoma (Nelson et al. 2019)
 - ALK in epithelioid fibrous histiocytoma (Dickson et al. 2018).

Melanocytic neoplasms with mesenchymal differentiation / Mesenchymal tumours with melanotic differentiation.

- melanocytes can arise indirectly from ventromedial neural crest-derived Schwann cell precursors.

4 broad categories:

1. Collision composed of two distinct neoplasms that abut one another by chance.
eg. melanocytic nevus lying adjacent to a neurofibroma
2. Melanocytic tumors exhibiting a neural morphology
eg. such as neurotized melanocytic naevi
3. Pigmented neural tumors that contain melanocytes
eg. Pigmented neurofibroma- in dark-skinned individuals, buttocks, head , legs
4. Non pigmented neural tumors that exhibit melanocytic differentiation.
eg. *Melanocytic differentiation is present in a significant proportion of nonpigmented diffuse neurofibromas, a potential diagnostic pitfall*
The American Journal of Surgical Pathology 37(8):p 1182-1191, August 2013.

MESENCHYMAL TUMOURS WITH MELANOCYtic IMMUNOPHENOTYPE

1. Perivascular epithelioid cell tumour (PECOMA)
2. Clear cell sarcoma
3. Clear cell sarcoma like tumour of the GI tract
4. MITF Pathway activated tumours - (MITF- CREM 11, CRCTC1-TRIM 11, ACTIN-MITF FUSIONS)
5. Pigmented Dermatofibrosarcoma protruberans
6. Pigmented (melanotic) myoepithelial tumor of soft tissue with EWSR1-KLF17 fusion
7. Melanotic neuroectodermal tumour of infancy
8. CRCTC1- TRIM 11 FUSION NEOPLASM
9. TFE3-NONO FUSION NEOPLASM (CASE 247)
10. SPECC1L::ALK FUSION NEOPLASM (CASE 248)

CONCLUSIONS

1. Cutaneous neoplastic proliferation that exhibits morphologic or immunohistochemical evidence of melanocytic differentiation does not necessarily lie within the nevus-melanoma spectrum
2. NGS and other molecular techniques are critical in the diagnosis and potentially prognosticating these entities.
3. Requirement of a national group (representatives of the 7 GLHs to share experience)